

# Clinical examination of various jaw fractures and evaluation of open and closed reductions: Six case reports

Tahir Ataözden<sup>1</sup>, Mustafa Mert Başaran<sup>2</sup>, Semanur Özüdoğru<sup>3</sup>

<sup>1</sup> Kafkas University, Faculty of Dentistry, Department of Oral and Maxillofacial Surgery, Kars, Turkey

<sup>2</sup> Kafkas University, Faculty of Medicine, Department of Otorhinolaryngology, Kars, Turkey

<sup>3</sup> Kafkas University, Faculty of Dentistry, Department of Pedodontics, Kars, Turkey

## Correspondence:

Dr. Tahir ATAÖZDEN

Kafkas University, Faculty of  
Dentistry, Department of Oral and  
Maxillofacial Surgery, Kars,  
Turkey

E-mail: [ataozdentahir@gmail.com](mailto:ataozdentahir@gmail.com)

Received: 4 February 2021

Accepted: 13 May 2021

## Abstract

**Aim:** This study aims to present the fracture types and treatment methods of jaw fracture cases that presented at our center.

**Methodology:** Of six presenting cases, two were angulus, one was parasymphysis, three were subcondylar, and one was a medial condyle fracture only. All patients were evaluated both clinically and radiologically by CT of the atlanto-occipital joint. We managed two of the mandibular fractures with open and closed reduction (mixed) and four with closed reduction only. Dislocation was observed in only two patients. Internal fixation was performed using either mini plates (Medartis, Basel, Switzerland) or mini-screws. All cases united within three weeks to three months.

**Results:** After analyzing the epidemiology of six fractures and the outcomes of the surgical treatment, as well as assessing the complications related to the surgical procedures, it was determined that in cases with dislocation, bimaxillary fixation should be applied as a maintenance to open reduction therapy. In cases without dislocation, bimaxillary fixation only is sufficient.

**Conclusion:** An analysis of dislocation conditions according to fracture type supports that the incidence of dislocation is low in condyle fractures.

**Keywords:** jaw fractures, clinical examination, open reduction, closed reduction.

## Access Online



DOI:

10.5577/intdentres.2021.vol11.suppl1.40

**How to cite this article:** Ataözden T, Başaran MM, Özüdoğru S. Clinical examination of various jaw fractures and evaluation of open and closed reductions: Six case reports. Int Dent Res 2021;11(Suppl.1):274-8. <https://doi.org/10.5577/intdentres.2021.vol11.suppl1.40>

## Introduction

Although the mandible is the largest and strongest bone of the face, it is the most common bone fractured as a result of facial traumas due to its location and protruding structure. Mandibular fractures are found in the midline, parasymphysis, symphysis, corpus, angulus, ramus, condyle, and coronoid and alveolar processes. Condyle fractures cover a significant

percentage of the fractures occurring in the mandible (1-3). The common cause of condyle fractures in adults is traffic accidents. While the most common causes in children are falling and bicycle accidents, traffic accidents are also a significant cause (4). Villareal et al. (5), Erol et al. (6), and Santler et al. (7) reported traffic accidents as the most common cause of condyle fractures, with rates of 63.1%, 38%, and 55%, respectively.

In the Lindahl classification system, the anatomical level of the fracture is divided into three groups based on the relationship between the mandibular segment and the condyle segment and the relationship between the condyle head and the glenoid fossa. In this classification system, the fracture level is described as subcondylar, condyle neck, or condyle head. A subcondylar fracture occurs from the sigmoid notch to the posterior mandible just below the condyle neck. With a condylar neck fracture, there is thin skin just below the condyle head, and it is in a narrow space. The condyle head fracture is the type of fracture that occurs at or above the ligament connections (8). Fractures related to the articular surface or toward the condyle neck constitute intracapsular fractures, and those below the condyle neck constitute extracapsular fractures (4).

The two main treatment methods for jaw fractures include open and closed reduction. Many factors, such as the level of the fracture, the direction and degree of displacement of the fractured segment, the patient's age and medical condition, the presence of other fractures, the condition of the teeth, and the surgeon's experience, must be considered when deciding whether to implement open or closed reduction (5). In closed reduction (or conservative treatment), immobilization is achieved by intermaxillary fixation (IMF) with the help of splints, IMF screws or brackets, especially arch bars, and especially in children, recovery and adaptation (9). Due to its near-perfect potential, IMF is seen as a standard treatment approach. Conservative treatment is widely preferred (4-7) because it does not have surgical risks, such as facial nerve damage and scar formation (10). Although the recommended application period for IMF is 2-4 weeks, early immobilization and functional rehabilitation of the jaw should be considered (11). In open reduction, the fracture line is surgically approached, and fracture fragments are fixed with the help of intraosseous wiring, lag screws, Kirschner wires, and plates (12). Today, these systems have been replaced by miniplate and screw systems that provide three-dimensional stabilization (13).

A full head and neck examination should be performed on patients being evaluated for maxillofacial trauma. A hematoma on the patient's skin or the floor of the mouth, loss of sensation in the chin and lips, and facial asymmetry or deformity at the front and profile can provide important information at first glance. Serious airway distress can be seen in bilateral mandibular corpus fractures. Anesthesia in the lower lip is a sign of a fracture line that runs distal to the mandibular foramen. Laceration of the gingiva in the fracture line is quite common. However, in cases of laceration of the skin, the presence of a severely comminuted and split fracture should be considered. Evaluation of the condition of the teeth and occlusion is one of the most important parts of diagnosis (14-16).

Here, we present an analysis of the treatment methods used in six mandibular fracture cases.

## Case Reports

### Case report I

A 30-year-old male involved in a traffic accident was admitted to our institution. The patient was hospitalized for one week with a condyle fracture. There was no dislocation. The patient was treated with closed reduction (Fig. 1b).

### Case report II

A 35-year-old female who was beaten was admitted to our institution. A CT of the atlanto-occipital joint showed a condyle fracture of the left medial condyle with limited displacement of the fragment. The patient was hospitalized for one week and treated with closed reduction by bimaxillary fixation (Fig. 1a).

### Case report III

A 14-year-old male involved in a horseback riding crash was admitted to our institution. A CT of the atlanto-occipital joint showed an angulus fracture with inferior-lingual displacement of the fragment and an advanced degree of dislocation in the canine area of the parasymphysis fracture. The patient was treated with open reduction, and bimaxillary fixation was performed (Fig. 2a-d).

### Case report IV

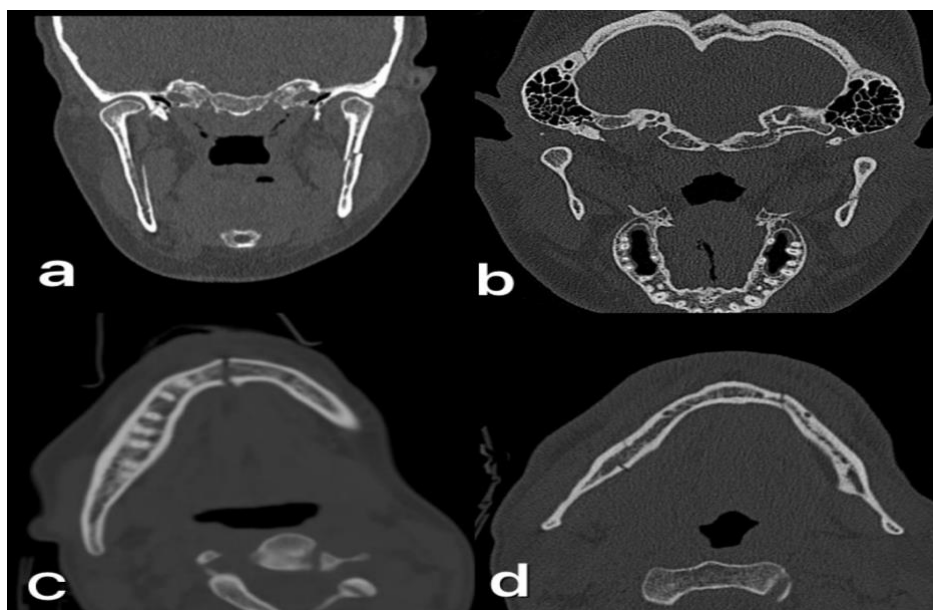
A 32-year-old male involved in a traffic accident was admitted to our institution. A subcondylar fracture was observed. The treatment of the patient was completed by bimaxillary fixation in the form of closed reduction. No dislocation was observed in the fracture line.

### Case report V

A 15-year-old female who fell from the 5th floor was admitted to our institution. Soft tissue injuries were observed in the neck, under the chin, and on the lips and nose of the patient. Neck, mandibula, and nose fractures were diagnosed upon examination (Fig. 3a-d). A CT of the atlanto-occipital joint showed a symphysis fracture (Fig. 1c). The patient was kept under observation in the intensive care unit for two days due to head trauma, after which she underwent open and closed reduction. Treatment was then continued with the bimaxillary fixation method.

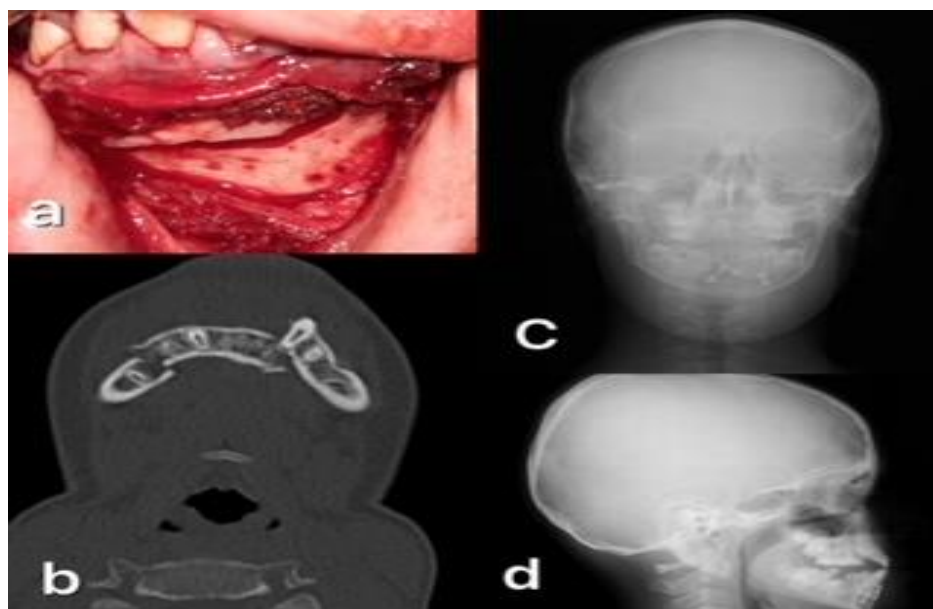
### Case report VI

A 36-year-old man involved in a traffic accident was admitted to our institution. There was an angulus fracture. There was no dislocation. The patient was treated with closed reduction (Fig. 1d).



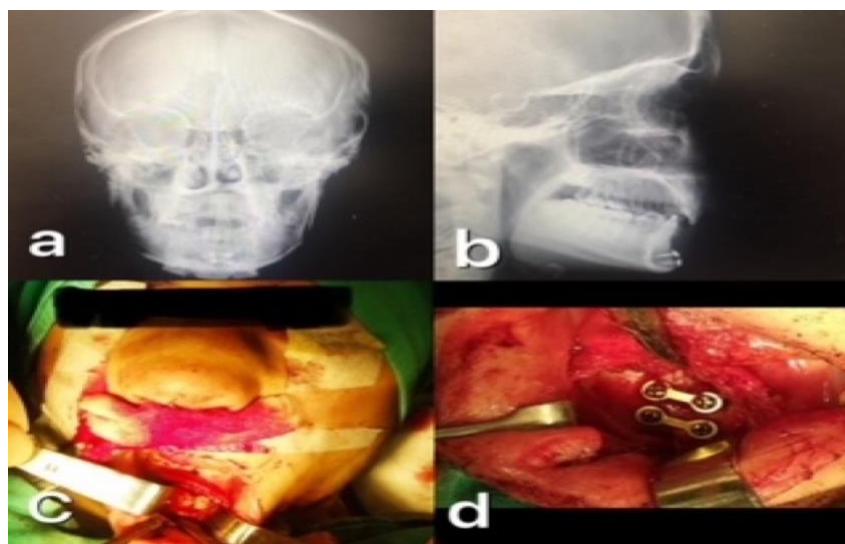
**Figure 1.**

- (a) Case II preoperative radiography showing condyle fracture
- (b) Case I preoperative radiography showing condyle fracture
- (c) Case V preoperative radiography showing parasymphysis fracture
- (d) Case VI preoperative radiography showing angulus fracture



**Figure 2.** Case III

- (a) photograph before the operation
- (b) CT showing fracture
- (c) PA radiography showing the placed mini plates
- (d) Lateral oblique radiography after the operation



**Figure 3.** Case V

- (a) PA radiography showing placed miniplate parasymphysis
- (b) Lateral oblique radiography
- (c) pre-operative images
- (d) photograph after the operation.

## Results

While there was no dislocation in two of the condylar fractures, dislocation was observed in another condyle and angulus fracture case. In cases with dislocation, bimaxillary fixation was applied as maintenance to open reduction treatment. Bimaxillary fixation was sufficient in cases without dislocation. It has been found that the incidence of dislocation is low in condyle fractures.

## Discussion

Although traffic accidents were reported as the most common cause of condyle fractures in previous studies in the literature, there are changes in the order of etiological factors due to various reasons in different geographical regions (2). Yaman et al. in their study including 146 condyle fractures, traffic accidents were 19.5% (17). They ranked third with falling from height (45%) and falling from height (21%) in the first place. In a similar study of 55 cases, Undt et al. reported fighting (20 cases) as the most common etiological cause of condyle fractures (18). In our study, the causes of fractures were reported as traffic accidents, horse strikes, assaults, and falling from height.

Bormann et al. found 42% condylar, 21% symphysis or parasymphysis, 20% angulus, 15% horizontal ramus, 2% ramus, and 0.3% coronoid fractures in their study, which consisted of 444 patients and evaluated the etiology and incidence of mandible fractures (19). Villareal et al. reported that mandibular condyle fractures (5). They stated that they constitute 29-40% of facial fractures and 20-62% of mandible fractures. In this study, although there are more cases of cone fractures, angulus, and parasymphysis fractures are also seen (5).

Brandt et al. in their literature search; Although there are problems such as temporary facial nerve paralysis and scar formation in internal fixation of mandibular condyle fractures by open reduction; reported that many problems such as chronic pain, malocclusion, asymmetry, restricted movement, and radiographic abnormalities are seen in patients treated with IMF conservatively; therefore, open reduction should be preferred in similar situations and indications (20). However, in our study, such complications did not occur in cases treated with open reduction.

In patients with bilateral condyle or angulus fractures after trauma, contact of the posterior teeth before the anterior teeth are closed, suggests an anterior open mouth deformity. In the opposite case where the molar teeth do not contact (posterior open mouth deformity), anterior alveolar fracture or parasymphysis fracture is likely to be seen. In our study, similar findings were observed in cases with angular fracture and condyle fracture. Ellis et al. evaluated occlusal outcomes in 142 patients with unilateral condyle fractures and reported significant malocclusion in patients treated with closed reduction (21). In our study, possible open mouth deformity and malocclusion were prevented by applying bimaxillary fixation therapy following open and closed reduction. Among the fractures in the mandible, condyle fractures cover a significant percentage. Many studies are showing the advantages of open and closed reduction, which are the two main methods used in the treatment of condyle fractures. For this reason, the treatment methods of condyle fractures have been a frequently discussed issue from the past to the present. The main purpose in condyle fractures; to prevent the development of functional and anatomical disorders that may occur in the future by using the appropriate treatment method. In this article, the treatment method of condyle fractures varied according to the location, and complete recovery was achieved in all cases.



## Conclusions

Open reduction internal fixation of condylar fractures is safe and reliable if used for good indications. Anatomical reduction and bimaxillar fixation is the key to good fracture healing.

**Acknowledgments:** This study was presented as a full-text oral presentation at the 1<sup>st</sup> International Dental Research and Health Sciences Congress held between 20-22 May 2021.

**Patient Consent for Publication:** Written informed consent was obtained from the patients.

**Peer-review:** Externally peer-reviewed.

**Author Contributions:** Conception - T.A.; Design - M.M.B.; Supervision - S.Ö.; Materials - T.A.; Data Collection and/or Processing - M.M.B.; Analysis and/or Interpretation - S.Ö.; Literature Review - T.A.; Writer - M.M.B.; Critical Review - S.Ö.

**Conflict of Interest:** No conflict of interest was declared by the authors.

**Financial Disclosure:** The authors declared that this study has received no financial support.

## References

- Ozgenel GY, Bayraktar A, Ozbek S, Akin S, Kahveci R, Ozcan M. A retrospective analysis of 204 mandibular fractures. Turkish journal of trauma & emergency surgery: TJTES, 2004;10(1):47-50.
- Marker P, Nielsen A, Bastian HL. (). Fractures of the mandibular condyle. Part 1: patterns of distribution of types and causes of fractures in 348 patients. British journal of oral and maxillofacial surgery, 2000;38(5):417-421. ([Crossref](#))
- Zachariades N, Mezitis M, Mourouzis C, Papadakis D, Spanou A. Fractures of the mandibular condyle: a review of 466 cases. Literature review, reflections on treatment and proposals. Journal of Cranio-Maxillofacial Surgery, 2006;34(7), 421-432. ([Crossref](#))
- Kademani D, Rombach D, Quinn P. Trauma to the temporomandibular joint region. In: Fonseca R, editor. Oral and Maxillofacial Trauma. Missouri: Elsevier saunders 2005. p. 523-568.
- Villarreal PM, Monje F, Junquera LM, Mateo J, Morillo AJ, González C. Mandibular condyle fractures: determinants of treatment and outcome. Journal of oral and maxillofacial surgery, 2004;62(2), 155-163. ([Crossref](#))
- Erol B, Tanrikulu R, Görgün B. Maxillofacial fractures. Analysis of demographic distribution and treatment in 2901 patients (25-year experience). Journal of Cranio-Maxillofacial Surgery, 2004;32(5), 308-313. ([Crossref](#))
- Santler G, Kärcher H, Ruda C, Köle E. Fractures of the condylar process: surgical versus nonsurgical treatment. Journal of oral and maxillofacial surgery, 1999;57(4), 392-397. ([Crossref](#))
- Lindahl L. Condylar fractures of the mandible: I. Classification and relation to age, occlusion, and concomitant injuries of teeth and teeth-supporting structures, and fractures of the mandibular body. International journal of oral surgery, 1977;6(1), 12-21. ([Crossref](#))
- Sickels J, Parks W. Temporomandibular joint region injuries. Oral and Maxillofacial Surgery. Philadelphia: Saunders Company, 2000;136-148.
- Assael LA. Open versus closed reduction of adult mandibular condyle fractures: an alternative interpretation of the evidence. Journal of oral and maxillofacial surgery, 2003;61(11), 1333-1339. ([Crossref](#))
- Zachariades N, Mezitis M, Mourouzis C, Papadakis D, Spanou A. Fractures of the mandibular condyle: a review of 466 cases. Literature review, reflections on treatment and proposals. Journal of Cranio-Maxillofacial Surgery, 2006;34(7), 421-432. ([Crossref](#))
- Brandt MT, Haug RH. Open versus closed reduction of adult mandibular condyle fractures: a review of the literature regarding the evolution of current thoughts on management1. Journal of oral and maxillofacial surgery, 2003;61(11), 1324-1332. ([Crossref](#))
- Jaseema Farwin S. Comparison of 3D Titanium Plates and Conventional Titanium Miniplates for Fractures in Maxillofacial Region (Doctoral dissertation, Madha Dental College and Hospital, Chennai) (2020).
- McCormick RS, Putnam G. The management of facial trauma. Surgery (Oxford), 2018;36(10), 587-594. ([Crossref](#))
- Zrounba H, Lutz JC, Zink S, Wilk A. Epidemiology and treatment outcome of surgically treated mandibular condyle fractures. A five years retrospective study. Journal of Cranio-Maxillofacial Surgery, 2014;42(6), 879-884. ([Crossref](#))
- Omezli M, Ertunc DAYI, Ayrançi F, KAYA GS. Mandibular condyle fractures and treatment methods. Cumhuriyet Dental Journal, 2012;15(1), 63-70. ([Crossref](#))
- Yaman F, Atılğan S, Yılmaz U, Gorgun B. Mandibular condyle fractures: Retrospective analysis. Türkiye Klinikleri J Dental Sci, 2007;13, 48-54.
- Undt G, Kermer C, Rasse M, Sinko K, Ewers R. Transoral miniplate osteosynthesis of condylar neck fractures. Oral Surgery, Oral Medicine, Oral Pathology, Oral Radiology, and Endodontology, 1999;88(5), 534-543. ([Crossref](#))
- Bormann KH, WildS, Gellrich NC, Kokemüller H, Stühmer C, Schmelzeisen R, Schön R. Five-year retrospective study of mandibular fractures in Freiburg, Germany: incidence, etiology, treatment, and complications. Journal of oral and maxillofacial surgery, 2009;67(6), 1251-1255. ([Crossref](#))
- Brandt MT, Haug RH. Open versus closed reduction of adult mandibular condyle fractures: a review of the literature regarding the evolution of current thoughts on management1. Journal of oral and maxillofacial surgery, 2003;61(11), 1324-1332. ([Crossref](#))
- Ellis E 3rd, McFadden D, Simon P, Throckmorton G. Surgical complications with open treatment of mandibular condylar process fractures. J Oral Maxillofac Surg 2000;58(9):950-958 ([Crossref](#))