

Treatment of Odontogenic Keratocyst: A Case Report

Mahmut Koparal¹, Ozkan Adiguzel²

¹Adiyaman University, Faculty of Dentistry, Department of Oral and Maxillofacial Surgery, Adiyaman, Turkey

²Dicle University, Faculty of Dentistry, Department of Endodontics, Diyarbakir, Turkey

Correspondence:

Mahmut Koparal
Adiyaman University, Faculty of
Dentistry, Department of
Department of Oral and
Maxillofacial Surgery,
Adiyaman, TURKEY
e-mail:dr.mahmutkoparal@gmail.com

Received 29 September 2015

Accepted 20 December 2015

Access Online



DOI

10.5577/intdentres.
2016.vol6.no1.3

Abstract

Aim: Odontogenic keratocysts are aggressive lesions characterised by a high recurrence risk ratio due to dental lamina residues in mandibular and maxillary regions. Odontogenic keratocysts appear distinct from other jaw cysts.

Methodology: In this report, a 35-year-old male patient was admitted to our clinic with numbness in the left mandible; the patient had also been admitted approximately 1 year previously complaining of paraesthesia, which subsequently progressed to complete numbness. During intraoral examination luxation was detected in the mandibular left second molar tooth. No caries or periodontal abnormalities were observed. In panoramic images a radiolucent lesion was detected, with regular boundaries, in the area of interest.

Results: The mass was enucleated under local anaesthesia and second molar teeth were extracted. During histopathological examination the mass was determined as a keratocyst.

Conclusions: In the present case, surgical treatment was performed.

Keywords: Odontogenic keratocyst, jaw cyst, aggressive lesion

How to cite this article: Koparal M, Adiguzel O. Treatment of Odontogenic Keratocyst: A Case Report. Int Dent Res 2016;6:13-15.

Introduction

Odontogenic keratocysts constitute between 3-10% of all jaw cysts, and are typically observed in male patients between 20 and 40 years of age, particularly in mandibular areas such as the third molar, ramus and angle of the mandible (1). Odontogenic keratocysts, for which specific clinical diagnostic criteria are lacking, may not be noticed until they become asymmetric or cause a secondary

infection, or until a fistula forms inside the mouth (2). Asymptomatic keratocyst progression also causes complications by compressing adjacent anatomical formations. In our patient, the loss of feeling that occasionally occurs following keratocyst removal under anaesthesia, due to nerve compression, was observed.

Case Report

During clinical examination of our 35-year-old male patient, admitted with numbness in the left mandible, luxation was detected in the left second molar tooth (Fig. 1), but no caries were observed. A panoramic radiograph was acquired for further study, revealing a wide, radiolucent lesion with regular boundaries in the left angle of the mandible and second molar tooth (Fig. 2). Under local anaesthesia, the mass was totally enucleated as a single piece (Fig. 3). The second molar tooth was extracted (Fig. 4); histopathological examination determined that the lesion was a keratocyst (Figure 5).

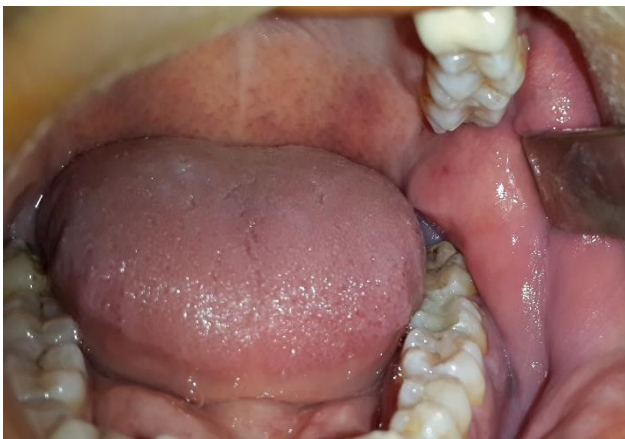

Figure 1. Intraoral view before surgery operation.

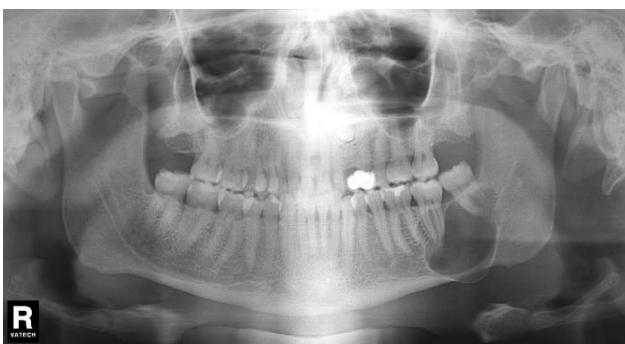


Figure 2. Appearance of radiolucent lesion.

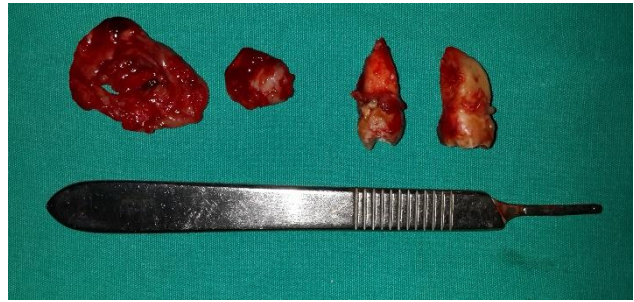


Figure 3. After surgery operation.

Outcome and Follow-Up

No recurrence has been detected during the 4-year follow-up; we continue to follow the patient.

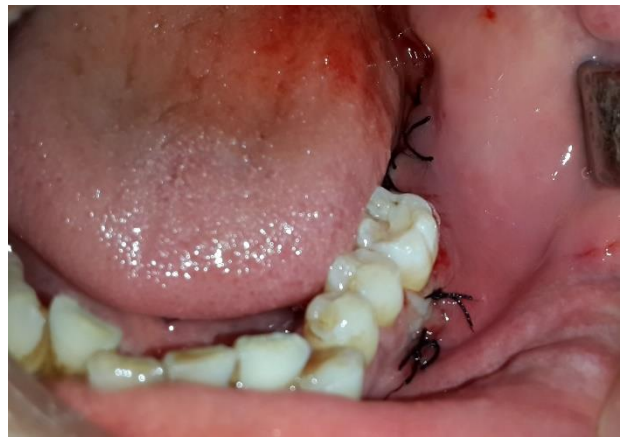

Figure 4. Intraoral view after surgery operation.

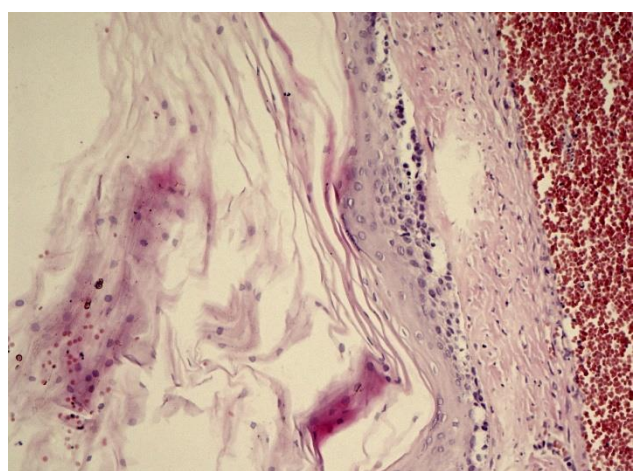


Figure 5. Histopathological view

Discussion

Odontogenic keratocysts represent the most-aggressive variety of jaw cyst, and may also be associated with nevoid basal cell carcinoma (3). Odontogenic keratocysts appear similar to other jaw cysts during radiography, and are characterised by typical histological images. It was reported previously that odontogenic keratocyst prevalence is two-fold higher in mandibular vs. maxillary regions (4). Odontogenic keratocysts are commonly observed in the angle of the mandible and ramus regions, and may spread toward the buccal bone. In our patient spreading toward the inferior region was also observed, causing compression and numbness in the inferior alveolar nerve. Similar to the treatment of other types of cysts, marsupialisation and surgery are typically performed to treat keratocysts; due to the higher recurrence risk ratio of odontogenic keratocysts, conservative treatment is usually not preferred. In addition to surgical treatment, irrigation of the region following surgery, using Carnoy's solution, is recommended (5). In our case, surgical treatment was performed, but Carnoy's solution was not used due to close proximity to the nerve.

Conclusions

Keratocysts are initially asymptomatic, clinically progressive and fast-growing lesions, which should be eliminated following routine radiographic examination. Because it is an infrequent neurological condition, loss of feeling in the jaws should be considered indicative of potential pathology.

Acknowledgments

The authors deny any conflicts of interest related to this study.

References

1. Cioffi GA, Terezhalmay GT, Del Balso AM. Odontogenic keratocyst of the maxillary sinus. *Oral Surg Oral Med Oral Pathol* 1987;64:648–51. [Crossref](#)
2. Blanas N, Freund B, Schwartz M, Furst IM. Systematic review of the treatment and prognosis of the odontogenic keratocyst. *Oral Surg Oral Med Oral Pathol Oral Radiol Endod* 2000;90:553–8. [Crossref](#)
3. Kalantar Motamedi MH. Aneurysmal bone cyst of the jaws: clinicopathological features, radiographic evaluation and treatment analysis of 17 cases. *J Craniomaxillofac Surg* 1998;26:56–62. [Crossref](#)
4. Campanacci M. Aneurysmal bone cyst. In: Campanacci M, editor. *Bone, soft tissue tumors*. 2nd ed. New York, NY: Springer Verlag; p. 812–40, 1999. [Crossref](#)
5. Dorfman HD, Czerniak B. Cystic lesions. In: Dorfman HD, Czerniak B, editors. *Bone tumors*. St. Louis, MO: Mosby; p. 855–912, 1998.