

Analysis of whether or not the alveolar palatine bone thickness of the central incisors is sufficient for implants of 3 mm and 3.5 mm thickness using cone-beam computed tomography

Devrim Deniz Üner¹, Bozan Serhat İzol²

¹ Harran University, Faculty of Dentistry, Department of Periodontology, Şanlıurfa, Turkey.

² Bingöl University, Faculty of Dentistry, Department of Periodontology, Bingöl, Turkey.

Correspondence:

Dr. Devrim Deniz ÜNER
Harran University, Faculty of Dentistry,
Department of Periodontology,
Şanlıurfa, Turkey.

E-mail: dvrmdnznr@gmail.com

Received: 7 December 2018

Accepted: 11 July 2019

Access Online



DOI:

10.5577/intdentres.2019.vol9.no2.3

Abstract

Aim: The purpose of this study was to investigate the alveolar palatine bone thickness of the maxillary central incisors using cone-beam computed tomography (CBCT).

Methodology: This study used the CBCT images of 480 patients (240 male - 240 female). In order to determine bone thickness, measurements were made on the program perpendicularly to the long axis of the tooth at 3 points selected from the 3, 6 and 9 mm apical or the enamel-cement border in parallel to the long axis of the central teeth.

Results: For the left central teeth, the mean palatine bone thickness was found for the coronal, medial and apical regions as 1.48 mm, 3.09 mm and 5.13 mm, respectively, while these values were respectively 1.35 mm, 2.95 mm and 5.10 mm for the right side.

Conclusions: Considering that there should be a bone of at least 1 mm thickness on socket walls for immediate implantation, it was determined that palatine bone thickness is not sufficient by itself for immediate implantation. As a result of the analysis, it was seen that the palatine alveolar bone thickness that was observed in women was thinner than that in men.

Keywords: Immediate implantation, anterior palatine alveolar bone, cone-beam computed tomography,

How to cite this article: Üner DD, İzol BS. Analysis of whether or not the alveolar palatine bone thickness of the central incisors is sufficient for implants of 3 mm and 3.5 mm thickness using cone-beam computed tomography. Int Dent Res 2019;9(2):51-7.

Introduction

Oral rehabilitation with implant-supported prosthetics lead to successful results in the treatment of single or multiple missing teeth (1-3). Long-term success in dental implants is dependent on very careful

assessment of the dimensions of the alveolar bone that is resorbed. This is because having a bone of at least 1 mm thickness around the implant is important for its long-term success (4). Additionally, a thin alveolar bone leads to fenestration, separation and soft tissue dullness (5).

Bone resorption that takes place after a tooth is extracted leads to a crest structure that is not suitable for implant placement (6). After a tooth is

pulled out, a set of physiological events takes place in the socket space through the recovery time between tooth extraction and implant placement, most of such events are caused by bone resorption and reshaping of gums, and this usually leads to aesthetical and functional damage (7). The concept of placement of an implant right after pulling the tooth out to prevent these damages (immediate implantation) was firstly introduced in 1970s (8). Immediate implant placement has recently become increasingly popular as it reduces the treatment time, number of operations and loss of bone after tooth extraction (8, 9). On the other hand, researchers at the University of Gothenburg showed that significant dimensional changes that occur in the alveolar bone are also seen in the 4-12-week period after immediate implant placement (10-12). Regarding implant placement, previous studies reported the 2-year survival rate as 98.4% and the 4-year implant survival rate as 97.5% (13). The aesthetic success in treatment of missing teeth by implantation is dependent on the correct placement of the implant in all three dimensions (14). The maxillary anterior region is one of the most important areas that need to be examined in detail before implant placement. This is because it is believed that the dimensions and morphology of an alveolar crest have a direct effect on implant placement, aesthetical outcomes and the implant's stability (15).

The buccolingual alveolar width is determined by using various methods such as direct measurement during operation, Computed Tomography (CT), back mapping, transtomography and direct caliper measurement (16-19). Studies that compared these methods for alveolar width did not find a significant difference among them (19-21). Conventional radiographic techniques such as intraoral, panoramic and cephalometric imaging are standard methods that have been used for a long time in planning implant treatments (22). The radiographic methods provide only 2-dimensional information about the area where the implant will be placed (23). After Cone-Beam Computed Tomography (CBCT) started to be used in planning implant treatments, it has become the priority choice for planning implant treatments among 3-dimensional methods (24-26). CBCT is a method that provides detailed information about alveolar bone structure and anatomic structures (27). Bone measurements that are made by calipers and cephalometry are not considered to be reliable in terms of repeatability and accuracy as there are too many bone irregularities and these lead to errors in humans. CBCT has been used for a long time to measure the amount of buccal bone (28) and bone volume after regenerative periodontal treatment (29). There are several studies that were conducted to determine the thickness of the bone in the buccal and the palatal by CBCT while planning for implant placement (19, 30-33).

The purpose of this study is to ignore the buccal bone thickness around the central teeth and examine whether or not the existing palatine bone is sufficient for implant planning by using CBCT.

Materials and Methods

Selection of patients

For this study, approval was obtained from the Ethics Board of the Faculty of Dentistry at Dicle University (2018/4). The CBCT images to be used in the study were selected from among the cases that visited the Faculty of Dentistry at Dicle University for any reason. The reports of all patients were obtained by using the 3-dimensional CBCT device that is used at the hospital of our university (i-CAT®, Model 17-19, Imaging Sciences International, Hatfield, PA, USA). While positioning the patient, care was taken to ensure that the guide light lines that are created by the device were in parallel to the sagittal plane of the patients, and the horizontal line passed through the Frankfurt plane and was in parallel to the ground (Figure 3.2). The images were obtained in 8-9 seconds at 120 kVp, 5 mA. Additionally, voxel size in the CBCT imaging procedures was determined as 0.3 mm.

Inclusion criteria

1. Patients over the age of 21
2. Patients with clear CBCT images

Exclusion criteria

1. Patients with fillings in their central teeth
2. Patients who were receiving orthodontic treatment
3. Patients with crown-banding on their central teeth
4. Patients with periodontal problem detected in their central teeth
5. Patients with pathologies detected in the root apices of their central teeth

Method

The measurements on the CBCT images to be used were made on the program of the dental tomography device itself perpendicularly to the long axis of the tooth at 3 points selected from 3, 6 and 9 mm to the enamel-cement border orthogonally to the long axis of the central teeth in the sagittal direction (Figure 1). While making the measurements, these three points were named as the coronal, medial and apical trio. Considering that different brands of implants have different dimensions and diameters, we considered the diameter of the implant to be placed into the palatine bone to be 3 mm. We made our calculations based on the rule that at least 1 mm of healthy bone would remain around the implant. In order to determine whether or not there were differences between the groups (female-male) in terms of these measurement that were made in the sagittal direction for only the palatine bone, these values were separately grouped for men and women.

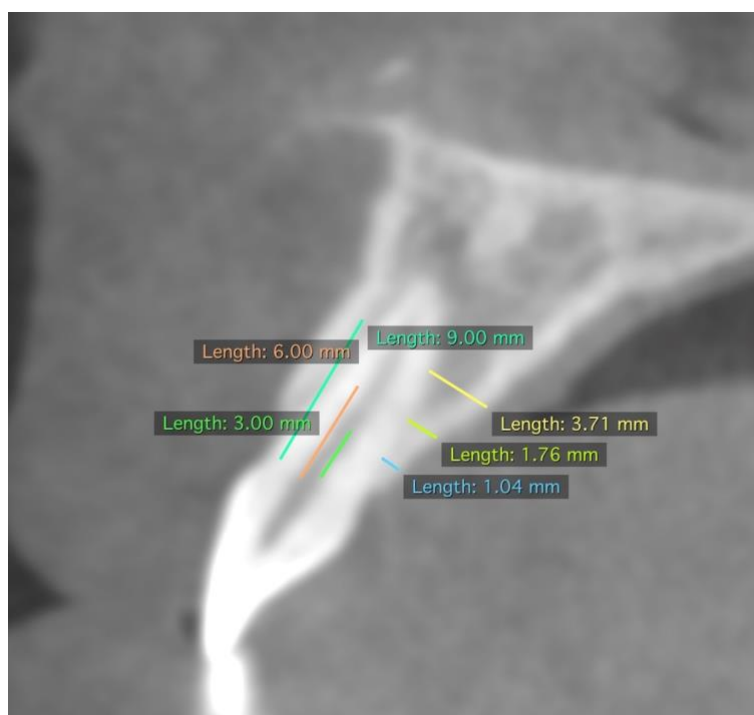


Figure 1. Measurements of the palatine bone at 3, 6 and 9 mm from the apical of the enamel-cement border

Statistical Analysis

The SPSS ver. 21 software was used for the statistical analysis. The normal distribution of the data was tested by using Shapiro-Wilk test in order to be able to choose between parametric and non-parametric tests. Descriptive statistics were used for the mean values of the measurements. Independent-samples t-Test was used to determine whether or not there was a significant difference between the groups (female-male). The value of $P < 0.05$ was accepted as statistically significant for all the statistical analysis methods that were used.

Results

Among the 480 patients with the age range of 21 to 54 (mean: 35.45), half were male, and the other half were female. For the left central teeth, the mean palatine bone thickness was found for the coronal, medial and apical regions as 1.48 mm, 3.09 mm and 5.13 mm, respectively, while these values were respectively 1.35 mm, 2.95 mm and 5.10 mm for the right side (Table 1).

For the women, in the left central teeth, the mean palatine bone thickness was found for the coronal, medial and apical regions as 1.51 mm, 2.76

mm and 4.68 mm, respectively, while these values were respectively 1.32 mm, 2.72 mm and 4.83 mm for the right side. For the men, in the left central teeth, the mean palatine bone thickness was found for the coronal, medial and apical regions as 1.45 mm, 3.41 mm and 5.57 mm, respectively, while these values were respectively 1.32 mm, 3.18 mm and 5.38 mm for the right side (Table 2). As a result of the statistical analysis that was carried out to see whether or not there was a significant difference between the groups (female-male) in terms of palatine bone thickness, it was seen that the P value was smaller than .05 for the thickness in the medial of the left and right central teeth (in the left medial region: $p=0.018$, in the right medial region: $p=0.016$). Accordingly, the palatine bone thickness in the medial of the alveolar bone in the men was significantly higher than that of the women. Additionally, the thickness of the palatine bone in the apical of the left central bone was significantly higher in the men than the women ($p= 0.020$).

Considering only the palatine bone for immediate implantation and evaluating the obtained results, the palatine bone around that left and right central teeth was not sufficient for implementation of implants with diameters of 3.5 and 3 mm on the coronal and medial regions without needing any augmentation process.

Table 1. The mean values for the palatine alveolar bone for the right and left central teeth.

	N	Minimum	Maximum	Mean	Std. deviation
Left coronal region	480	.54	5.25	1.4830	.64118
Left medial region	480	.67	9.56	3.0903	1.23087
Left apical region	480	1.08	9.86	5.1310	1.73037
Right coronal region	480	.35	2.34	1.3546	.40718
Right medial region	480	1.00	4.96	2.9510	.86330
Right apical region	480	1.23	8.61	5.1071	1.39684
Total	480				

Table 2. The mean thickness of the palatal bone in the coronal, medial and apical regions for the men and the women.

	Sex	N	Mean	Std. Deviation	Std. Error of Mean
Left Coronal	Female	240	1.5115	.82932	.13113
Region	Male	240	1.4545	.37859	.05986
Left Medial	Female	240	2.7663	1.08217	.17111
Region	Male	240	3.4143	1.29711	.20509
Left Apical	Female	240	4.6850	1.72633	.27296
Region	Male	240	5.5770	1.63612	.25869
Right Coronal	Female	240	1.3208	.43707	.06911
Region	Male	240	1.3885	.37744	.05968
Right Medial	Female	240	2.7203	.80392	.12711
Region	Male	240	3.1818	.86844	.13731
Right Apical	Female	240	4.8330	1.31284	.20758
Region	Male	240	5.3813	1.44036	.22774

Discussion

The purpose of this study was to determine the palatine bone thickness values around the central teeth in a group of 480 patient living in Turkey by using CBCT images and assess whether or not there were significant differences between the men and the women. Several

studies have been conducted in the practice of planting implants into the extraction socket immediately after tooth extraction. There is an adequate number of studies which provided information on long-term outcomes and reported that immediate implant placement and delayed implant placement have similar implant survival rates (34). The long-term clinical

success of dental implants is largely dependent on the amount of bone and attached gingival tissue around the implant (35). After tooth extraction, a reduction of width and height takes place in the alveolar crest in the alveolar bone in the course of a few month following the extraction (10, 11). While previous studies followed the idea that implants that are placed immediately after tooth extraction stop alveolar resorption (36, 37) more recent studies have shown that the alveolar bone is resorbed in the process following immediate implantation, too (10, 38). In the light of this information, we also saw that the thickness of the alveolar socket walls in the region planned for immediate implementation is important for long-term success, and we planned this study by considering that it is important to have information on palatine bone thickness in the region where aesthetical problems are prominent such as the maxillary central teeth.

In a previous study, Zainab et al. found the palatal bone thickness around the left central tooth in the crests, medial root and apical respectively as 0.50 ± 0.4 mm, 1.74 ± 1.06 mm and 2.38 ± 1.31 mm, while these values for the right central tooth were respectively 0.8 ± 0.36 mm, 1.9 ± 0.91 mm and 2.49 ± 1.01 mm (39). In a study that was similar to ours, Al Tarawneh et al. reported the palatine bone thickness for the central teeth in the coronal, medial and apical regions as 1.068 ± 0.38 mm, 1.66 ± 0.71 mm and 3.13 ± 1.26 mm (40). Lee et al., as a result of similar measurements, reported the palatal bone thickness in the central teeth at 3 mm from the enamel-cement border as 1.53 ± 0.55 mm (41). In our study, the mean palatine bone thickness in the coronal region for the right and left central teeth as 1.3 and 1.5 mm, respectively. While these values were respectively found as 2.95 and 3.05 mm for the medial region, they were respectively 5.10 and 5.13 mm for the apical region. In comparison to the results of previous studies, while our study reached similar thickness values in the coronal region, the results in our study in other regions (medial and apical) were higher. Additionally, our study also reached the finding in other studies that the bone thickness in the coronal palatal region was the lowest, while the bone thickness in the apical region was the highest.

In a similar study, Zhang et al. reported that the bone thickness around the maxillary anterior teeth was higher in men than women (42). There are several studies which reported that the alveolar bone in men is thicker than that in women (39, 43-46).

Conclusions

In our study, we determined that the alveolar bone thickness in the palatal of the central teeth in the coronal, medial and apical regions was higher than 1 mm, the bone had a tendency to thicken from the coronal to the apical, and the alveolar bone thickness at the palatal was higher in the men in comparison to the women. When only the palatine bone thickness was considered, we determined that planning implementation by using the palatine bone only would

not be adequate when implants with diameters of 3.5 and 3 mm are used, because the implant's surface would be open in the coronal and medial regions towards the anterior face of the bone.

Consequently, considering the aim of having bone of at least 1 mm thickness on socket walls for immediate implantation, we may report that palatine bone thickness is not sufficient by itself in planning immediate implantation.

Ethical Approval: Ethics committee approval was received for this study from Harran University.

Peer-review: Externally peer-reviewed.

Author Contributions: Conception - D.D.Ü.; Design - B.S.İ., D.D.Ü.; Supervision - B.S.İ.; Materials - D.D.Ü., B.S.İ.; Data Collection and/or Processing - B.S.İ.; Analysis and/or Interpretation - B.S.İ.; Literature Review - D.D.Ü., Writer - D.D.Ü., Critical Review - B.S.İ.

Conflict of Interest: No conflict of interest was declared by the authors.

Financial Disclosure: The authors declared that this study has received no financial support.

References

1. Wennstrom JL, Ekestubbe A, Grondahl K, Karlsson S, Lindhe J. Oral rehabilitation with implant-supported fixed partial dentures in periodontitis-susceptible subjects. A 5-year prospective study. *J Clin Periodontol.* 2004;31:713-24. ([Crossref](#))
2. Romeo E, Lops D, Amorfini L, Chiapasco M, Ghisolfi M, Vogel G. Clinical and radiographic evaluation of small-diameter (3.3-mm) implants followed for 1-7 years: a longitudinal study. *Clin Oral Implants Res.* 2006;17:139-48. ([Crossref](#))
3. Karoussis IK, Salvi GE, Heitz-Mayfield LJ, Bragger U, Hammerle CH, Lang NP. Long-term implant prognosis in patients with and without a history of chronic periodontitis: a 10-year prospective cohort study of the ITI Dental Implant System. *Clin Oral Implants Res.* 2003;14:329-39. ([Crossref](#))
4. Chowdhary R, Chandraker N. Simple diagnostic method to assess the available bone for immediate implant placement in an extracted socket. *J Oral Implantol.* 2011;37:473-6. ([Crossref](#))
5. Braut V, Bornstein MM, Belser U, Buser D. Thickness of the anterior maxillary facial bone wall-a retrospective radiographic study using cone beam computed tomography. *Int J Periodontics Restorative Dent.* 2011;31:125-31.
6. Çakır M, Karaca İR. İmplant uygulamaları için kret koruma teknikleri. *Atatürk Univ Diş Hek Fak Derg.* 2015;25:107-18. ([Crossref](#))
7. Qian J, Wennerberg A, Albrektsson T. Reasons for marginal bone loss around oral implants. *Clin Implant Dent Relat Res.* 2012;14:792-807. ([Crossref](#))
8. Schulte W, Kleinekenscheidt H, Lindner K, Schareyka R. [The Tübingen immediate implant in clinical studies]. *Dtsch Zahnärztl Z.* 1978;33:348-59.
9. Esposito M, Grusovin MG, Polyzos IP, Felice P, Worthington HV. Timing of implant placement after tooth extraction: immediate, immediate-delayed or delayed implants? *A*

- Cochrane systematic review. *Eur J Oral Implantol*. 2010;3:189-205. ([Crossref](#))
10. Araujo MG, Lindhe J. Dimensional ridge alterations following tooth extraction. An experimental study in the dog. *J Clin Periodontol*. 2005;32:212-8. ([Crossref](#))
 11. Araujo MG, Sukekava F, Wennstrom JL, Lindhe J. Tissue modeling following implant placement in fresh extraction sockets. *Clin Oral Implants Res*. 2006;17:615-24. ([Crossref](#))
 12. Araujo MG, Wennstrom JL, Lindhe J. Modeling of the buccal and lingual bone walls of fresh extraction sites following implant installation. *Clin Oral Implants Res*. 2006;17:606-14. ([Crossref](#))
 13. Lang NP, Pun L, Lau KY, Li KY, Wong MC. A systematic review on survival and success rates of implants placed immediately into fresh extraction sockets after at least 1 year. *Clin Oral Implants Res*. 2012;23 Suppl 5:39-66. ([Crossref](#))
 14. Buser D, Martin W, Belser UC. Optimizing esthetics for implant restorations in the anterior maxilla: anatomic and surgical considerations. *Int J Oral Maxillofac Implants*. 2004;19 Suppl:43-61.
 15. Wakimoto M, Matsumura T, Ueno T, Mizukawa N, Yanagi Y, Iida S. Bone quality and quantity of the anterior maxillary trabecular bone in dental implant sites. *Clin Oral Implants Res*. 2012;23:1314-9. ([Crossref](#))
 16. Van Assche N, van Steenberghe D, Guerrero ME, Hirsch E, Schutyser F, Quirynen M, et al. Accuracy of implant placement based on pre-surgical planning of three-dimensional cone-beam images: a pilot study. *J Clin Periodontol*. 2007;34:816-21. ([Crossref](#))
 17. Wilson DJ. Ridge mapping for determination of alveolar ridge width. *Int J Oral Maxillofac Implants*. 1989;4:41-3.
 18. Bousquet F, Bousquet P, Vazquez L. Transtomography for implant placement guidance in non-invasive surgical procedures. *Dentomaxillofac Radiol*. 2007;36:229-33. ([Crossref](#))
 19. Chen LC, Lundgren T, Hallstrom H, Cherel F. Comparison of different methods of assessing alveolar ridge dimensions prior to dental implant placement. *J Periodontol*. 2008;79:401-5. ([Crossref](#))
 20. Chugh A, Bhisnoi P, Kalra D, Maggu S, Singh V. Comparative evaluation of three different methods for evaluating alveolar ridge dimension prior to implant placement: An in vivo study. *J Dent Implant*. 2013;3:101-10. ([Crossref](#))
 21. Eachempati P, Vynne OJ, Annishka A, Fickry FSS, Naurah MA, Idiculla JJ, et al. A Comparative Cross-Sectional Study of Pre-implant Site Assessment Using Ridge Mapping and Orthopantomography (OPG) with cone Beam Computed Tomography (CBCT). *Res J Pharm Biol Chem Sci*. 2016;7:1185-92.
 22. Harris D, Horner K, Grondahl K, Jacobs R, Helmrot E, Benic GI, et al. E.A.O. guidelines for the use of diagnostic imaging in implant dentistry 2011. A consensus workshop organized by the European Association for Osseointegration at the Medical University of Warsaw. *Clin Oral Implants Res*. 2012;23:1243-53. ([Crossref](#))
 23. Allen F, Smith DG. An assessment of the accuracy of ridge-mapping in planning implant therapy for the anterior maxilla. *Clin Oral Implants Res*. 2000;11:34-8. ([Crossref](#))
 24. Tyndall DA, Price JB, Tetradis S, Ganz SD, Hildebolt C, Scarfe WC. Position statement of the American Academy of Oral and Maxillofacial Radiology on selection criteria for the use of radiology in dental implantology with emphasis on cone beam computed tomography. *Oral Surg Oral Med Oral Pathol Oral Radiol*. 2012;113:817-26. ([Crossref](#))
 25. Benic GI, Elmasry M, Hammerle CH. Novel digital imaging techniques to assess the outcome in oral rehabilitation with dental implants: a narrative review. *Clin Oral Implants Res*. 2015;26 Suppl 11:86-96. ([Crossref](#))
 26. Hammerle CH, Cordaro L, van Assche N, Benic GI, Bornstein M, Gamper F, et al. Digital technologies to support planning, treatment, and fabrication processes and outcome assessments in implant dentistry. Summary and consensus statements. The 4th EAO consensus conference 2015. *Clin Oral Implants Res*. 2015;26 Suppl 11:97-101. ([Crossref](#))
 27. Laçin N AE, Veli İ. Cone-beam computed tomography evaluation of bifid mandibular canal. *Int Dent Res* 2018;8:78-83. ([Crossref](#))
 28. Rungcharassaeng K, Caruso JM, Kan JY, Kim J, Taylor G. Factors affecting buccal bone changes of maxillary posterior teeth after rapid maxillary expansion. *Am J Orthod Dentofacial Orthop*. 2007;132:428.e1-8. ([Crossref](#))
 29. Grimard BA, Hoidal MJ, Mills MP, Mellonig JT, Nummikoski PV, Mealey BL. Comparison of clinical, periapical radiograph, and cone-beam volume tomography measurement techniques for assessing bone level changes following regenerative periodontal therapy. *J Periodontol*. 2009;80:48-55. ([Crossref](#))
 30. Vera C, De Kok IJ, Reinhold D, Limpiphatanakorn P, Yap AK, Tyndall D, et al. Evaluation of buccal alveolar bone dimension of maxillary anterior and premolar teeth: a cone beam computed tomography investigation. *Int J Oral Maxillofac Implants*. 2012;27:1514-9. ([Crossref](#))
 31. El Nahass H, S NN. Analysis of the dimensions of the labial bone wall in the anterior maxilla: a cone-beam computed tomography study. *Clin Oral Implants Res*. 2015;26:e57-e61. ([Crossref](#))
 32. Ghassemian M, Nowzari H, Lajolo C, Verdugo F, Pirronti T, D'Addona A. The thickness of facial alveolar bone overlying healthy maxillary anterior teeth. *J Periodontol*. 2012;83:187-97. ([Crossref](#))
 33. Zekry A, Wang R, Chau AC, Lang NP. Facial alveolar bone wall width - a cone-beam computed tomography study in Asians. *Clin Oral Implants Res*. 2014;25:194-206. ([Crossref](#))
 34. Bhola M, Jacobs LC, Kolhatkar S. Immediate implants for aesthetic success: New guidelines. *J Int Clin Dent Res Org*. 2015;7:138. ([Crossref](#))
 35. Halperin-Sternfeld M, Zigdon-Giladi H, Machtei EE. The association between shallow vestibular depth and peri-implant parameters: a retrospective 6 years longitudinal study. *J Clin Periodontol*. 2016;43:305-10. ([Crossref](#))
 36. Denissen HW, Kalk W. Preventive implantations. *Int Dent J*. 1991;41:17-24.
 37. Sclar AG. Preserving alveolar ridge anatomy following tooth removal in conjunction with immediate implant placement. The Bio-Col technique. *Atlas Oral Maxillofac Surg Clin North Am*. 1999;7:39-59. ([Crossref](#))
 38. Cardaropoli G, Araujo M, Hayacibara R, Sukekava F, Lindhe J. Healing of extraction sockets and surgically produced - augmented and non-augmented - defects in the alveolar ridge. An experimental study in the dog. *J Clin Periodontol*. 2005;32:435-40. ([Crossref](#))
 39. Alsaffar ZJ, Shafshak SM, Shokry S. Assessment of Labial and Palatal Alveolar Bone Thickness and Height in Maxillary Anterior Teeth in Saudi population Using Cone Beam Computed Tomography (CBCT). *Int j contemp dent* 2016;7:1-6.
 40. AlTarawneh S, AlHadidi A, Hamdan AA, Shaqman M, Habib E. Assessment of Bone Dimensions in the Anterior Maxilla: A Cone Beam Computed Tomography Study. *J Prosthodont*. 2018;27:321-28. ([Crossref](#))
 41. Lee SL, Kim HJ, Son MK, Chung CH. Anthropometric analysis of maxillary anterior buccal bone of Korean adults using cone-beam CT. *J Adv Prosthodont*. 2010;2:92-6. ([Crossref](#))
 42. Zhang W, Skrypczak A, Weltman R. Anterior maxilla alveolar ridge dimension and morphology measurement by cone beam computerized tomography (CBCT) for immediate implant treatment planning. *BMC Oral Health*. 2015;15:65. ([Crossref](#))

43. Cassetta M, Sofan AA, Altieri F, Barbato E. Evaluation of alveolar cortical bone thickness and density for orthodontic mini-implant placement. *J Clin Exp Dent*. 2013;5:e245-52. [\(Crossref\)](#)
44. Nowzari H, Molayem S, Chiu CH, Rich SK. Cone beam computed tomographic measurement of maxillary central incisors to determine prevalence of facial alveolar bone width ≥ 2 mm. *Clin Implant Dent Relat Res*. 2012;14:595-602. [\(Crossref\)](#)
45. Braun S, Hnat WP, Freudenthaler JW, Marcotte MR, Honigle K, Johnson BE. A study of maximum bite force during growth and development. *Angle Orthod*. 1996;66:261-4. [\(Crossref\)](#)
46. Usui T, Uematsu S, Kanegae H, Morimoto T, Kurihara S. Change in maximum occlusal force in association with maxillofacial growth. *Orthod Craniofac Res*. 2007;10:226-34. [\(Crossref\)](#)