

# Prosthetic rehabilitation of a hypohidrotic ectodermal dysplasia patient: A case report

Dersim Gökce<sup>1</sup>, Emrah Ayna<sup>1</sup>, Zelal Seyfioğlu Polat<sup>1</sup>

<sup>1</sup> Dicle University, Faculty of Dentistry, Department of Prosthodontics, Diyarbakır, Turkey

## Abstract

**Aim:** Ectodermal dysplasia is a rare hereditary disease that arises from a developmental disorder of 2 or more ectoderm-derived tissues. Ectodermal dysplasia is seen in 3 different types: anhidrotic, hypohidrotic, and hidrotic. Its anhidrotic and hypohidrotic types are the most common. This study presents the intraoral findings and dental treatment approach of a case diagnosed with hidrotic ectodermal dysplasia that demonstrates the typical characteristics of the disease, such as anodontia, hypohydrosis (reduced sweating), hypotrichosis (sparse hair), and loss of vertical dimension.

**Methodology:** A 5-year-old male patient presented to the clinic of the Prosthetic Dental Treatment Department of the School of Dentistry at Dicle University on 25.10.2020 with complaint of missing teeth. A genetic analysis conducted in 2016 showed that he was a homozygous carrier of the p.Cys148Arg (c.442 T>C) mutation on the 5th exon of the ectodysplasin-A receptor (EDAR) gene. The mutation detected in the patient was associated with ectodermal dysplasia. An extraoral clinical examination revealed sparse hair, eyebrows, and eyelashes; soft, smooth, and dry skin; thin, linear wrinkles around the eyes and the lips; drooping, thickened lips; a sunken nose; fractured nails; hyperthermia due to lack of sweat glands; hyperkeratosis in the skin and soles of the feet; 2 nipples on one side of the chest; and reduced vertical facial height. An intraoral examination revealed anodontia; there were no teeth on the maxilla or the mandible and no radiographically identified tooth germ. Dry mouth due to a lack of sufficient saliva was another finding.

**Conclusion:** In this case report, in the presence of anodontia, a removable total prosthesis, which is a non-invasive treatment option, was applied. Production of endosseous implants was postponed for a later time following the patient's growth and development.

**Keywords:** ectodermal dysplasia, anodontia, child, prosthetic treatment

## Correspondence:

Dr. Dersim GÖKCE  
Dicle University, Faculty of Dentistry,  
Department of Prosthodontics,  
Diyarbakır, Turkey.  
E-mail: [dersim\\_gokce@hotmail.com](mailto:dersim_gokce@hotmail.com)

Received: 6 March 2021

Accepted: 19 May 2021

## Access Online



DOI:

10.5577/intdentres.2021.vol11.suppl1.43

**How to cite this article:** Gökce D, Ayna E, Seyfioğlu Polat Z. Prosthetic rehabilitation of a hypohidrotic ectodermal dysplasia patient: A case report. Int Dent Res 2021;11(Suppl.1):292-8. <https://doi.org/10.5577/intdentres.2021.vol11.suppl1.43>

## Introduction

Ectodermal dysplasia (ED) was defined for the first time by Thurman in 1848. Ectodermal dysplasia is a broad heterogeneous group of hereditary conditions in which at least 2 embryonic ectoderm-derived tissues

are involved (1). Its classical triad consists of tooth (hypodontia or anodontia), sweat gland (hypohydrosis or anhidrosis), and hair (hypotrichosis) anomalies. Other exocrine glands (i.e., the lacrimal gland), skin and nails, and other ectodermal structures may also be affected (2).

It has been reported that ED has approximately 200 different types (3, 4). ED is a very rare hereditary disease with an incidence of 1/100,000 (5).

ED is encountered in 3 different forms: anhidrotic, hypohidrotic, and hidrotic. The most frequently encountered types of ED are anhidrotic and hypohidrotic dysplasia. Anhidrotic ectodermal dysplasia, which is seen more rarely, is characterized by the lack of sebaceous glands and sweat glands. This syndrome is seen more frequently in women and exhibits autosomal recessive inheritance. In hidrotic ectodermal dysplasia, which exhibits autosomal recessive inheritance, the sebaceous and sweat glands are normal (3, 4, 6-10).

Among the types of ectodermal dysplasia, hypohidrotic ectodermal dysplasia (HED) is a condition characterized by the dysfunction or underdevelopment of ectodermal structures and their derivatives as a result of mesodermal and ectodermal disorders in embryonic development (11). HED, which is a frequently encountered form of ectodermal dysplasia, is a rare hereditary disease (12). Because HED may be sporadic, it is also characterized by autosomal dominant, autosomal recessive, and X-linked recessive forms of inheritance (2).

HED, which affects males more frequently and severely, exhibits clinical symptoms such as sparse hair and eyebrows and hypodontia as well as unilateral breast hypoplasia in female carriers (9, 13). A genetic map derived from the French-Canadian population, in which hypohidrotic ectodermal dysplasia is more prevalent, shows that ED also takes other hereditary forms. In addition, mutations in the EDAR and ectodysplasin-A (EDA) genes are responsible for autosomal hypohidrotic and X-linked ED (9, 14).

Patients with ED often exhibit the following symptoms: the hair, eyebrows, and eyelashes are thin, short, and sparse; the forehead and lips are prominent; and the nose is sunken. Moreover, thick wrinkles form around the eyes and mouth, and thickening, color changes, deformities, and dark pigmentation in the nails may also be observed (15).

Dysfunction of the salivary glands is seen in the anhidrotic and hypohidrotic types of ED. The more rarely seen type, anhidrotic ectodermal dysplasia, is characterized by the absence of sweat and sebaceous glands. In the more frequently seen hypohidrotic type, sebaceous and sweat glands are hypoplastic (6). In individuals with ED, due to the lack of some or all sweat and sebaceous glands, the skin is drier, smoother, and thinner. Additionally, hyperkeratosis may be observed in the palms and the soles of the feet (16-18).

Intraoral symptoms vary in ED cases. In addition to numerical anomalies such as hypodontia and anodontia, taurodontism, supernumerary teeth, the presence of natal/neonatal teeth, persistent primary teeth, and enamel hypoplasia are observed (19, 20). Both primary and adult teeth may be affected by these dental anomalies. However, cases in which all teeth are missing in both primary dentition and permanent dentition (anodontia) are very rare (21).

Jaw development in ED cases is normal, but the alveolar crests remain thin due to missing teeth. The

inability of the alveolar crests to form properly due to missing teeth leads to a decrease in vertical dimension and, therefore, a reduction in the height of the lower face. This is why the lips appear to be more swollen. In these patients, the palatine arch is deeper, and some cases may exhibit a cleft palate (22).

Due to the numerical deficiency in the primary and permanent teeth in childhood, ED cases require early dental treatment (15, 23). Early treatment is important in terms of improving chewing function and forming optimum facial appearance (15, 23). Early intervention facilitates normal development of chewing, swallowing, and speech in children. In addition to supporting the normal development of TMJ function, early intervention facilitates generally healthy growth and development (24).

As a treatment option, partial denture prosthetics are considered to be ideal. When teeth are present in ED cases, the existing teeth usually have a conical structure. Because this situation negatively affects retention, the use of overdenture prosthetics is recommended in these cases (15, 23, 25, 26).

Because of the presence of currently erupting teeth and continuation of jaw development in pediatric patients, the prosthetic treatment must be modified. Periodic follow-ups should be performed in parallel with growth and development, and the prosthetics should be replaced every 6 months (23).

In this reported case, the primary and permanent teeth of the patient were completely absent, which is rarely seen in hypohidrotic ectodermal dysplasia. It was aimed to examine the prosthetic rehabilitation of the patient, who experienced nutrition, aesthetic, functional, and phonation problems due to anodontia.

## Case Report

For the 5-year-old male patient who presented to the clinic of the Dicle University, Faculty of Dentistry, Department of the Prosthodontics on 25.10.2020 due to the complaint of missing teeth, a genetic analysis conducted in 2016 showed that he was a homozygous carrier of the p.Cys148Arg (c.442 T>C) mutation on the 5th exon of the EDAR gene. The mutation detected in the patient is associated with ectodermal dysplasia. The patient's mother and father, who were healthy and non-consanguineous, carried the p.Cys148Arg (c.442 T>C) mutation on the 5th exon of the EDAR gene in the heterozygous form. The disease was not identified in the twin siblings of the 5-year-old patient.

An extraoral clinical examination of the patient revealed sparsity in the hair (Figs. 1, 2), reduced vertical facial height (Fig. 3), eyebrows, and eyelashes; soft, smooth, dry skin; thin, linear wrinkles around the eyes and the lips (Fig. 4); drooping, thickened lips; a sunken nose (Fig. 4); fractured nails (Fig. 5); 2 nipples on one side of the chest (Fig. 6); and hyperthermia due to lack of sweat glands; hyperkeratosis in the skin and soles of the feet (Figs. 5, 7);

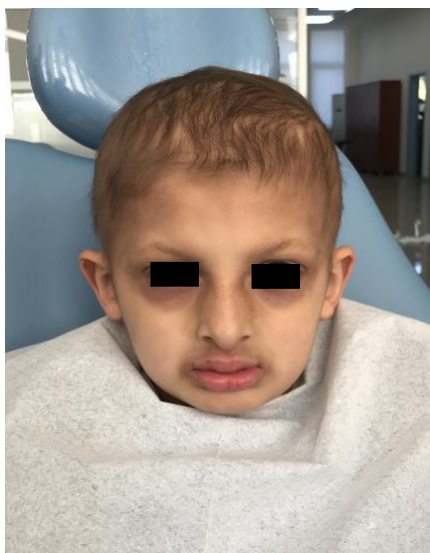

Figure 1. Frontal appearance of the patient

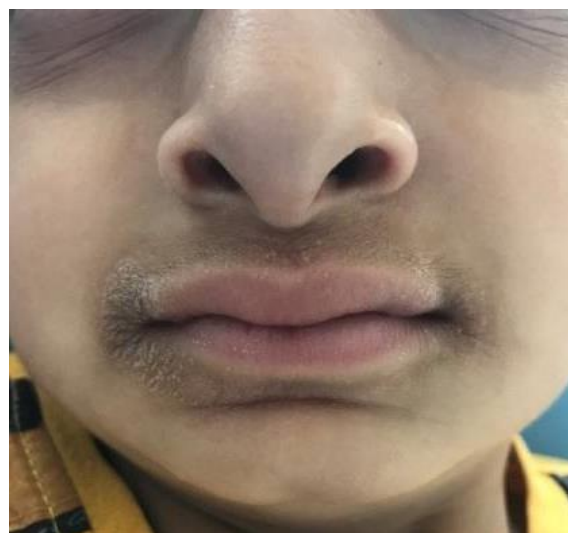

Figure 4. Think wrinkles found around the lips and eyes of the patient, appearance of saddle-shaped nose

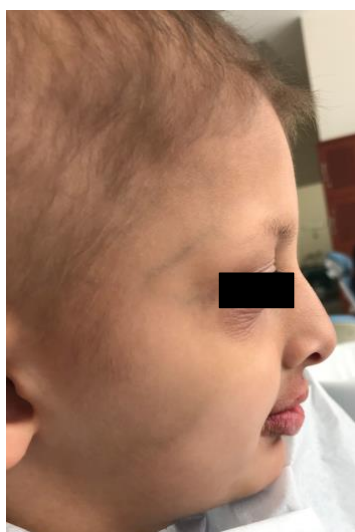

Figure 2. Lateral appearance of the patient, weak hair

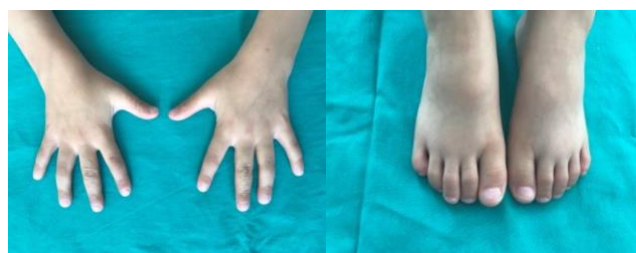

Figure 5. Appearance of thinning and fractures in the fingernails and toenails of the patient

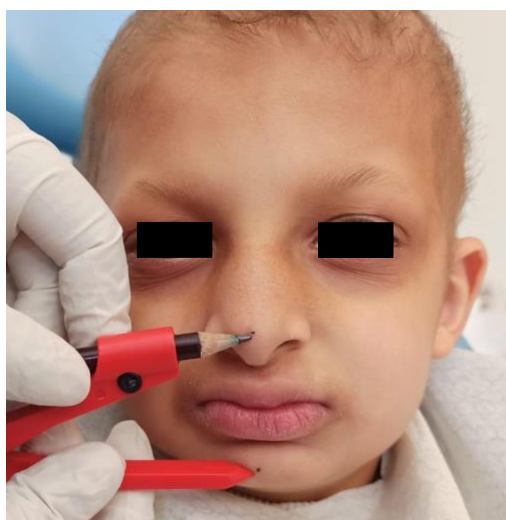


Figure 3. Reduced vertical dimension of the patient

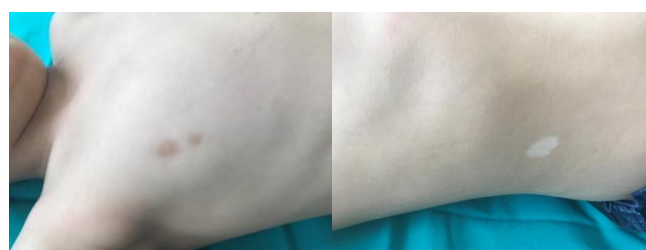
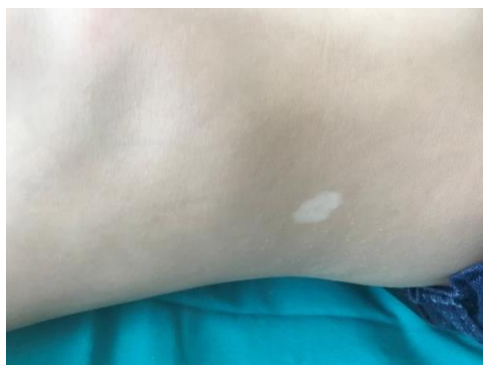
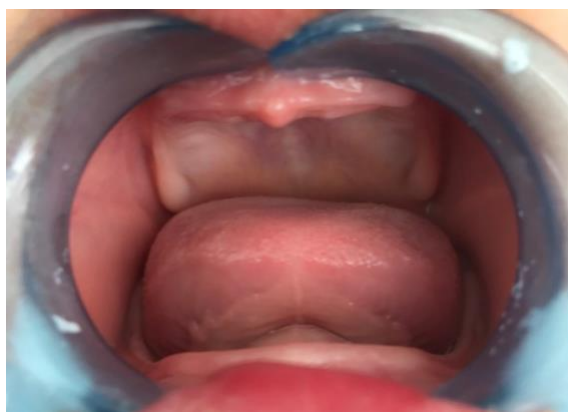
Figure 6. a. Double-nipple appearance in the patient. b. Appearance of scaling and spotting on the skin



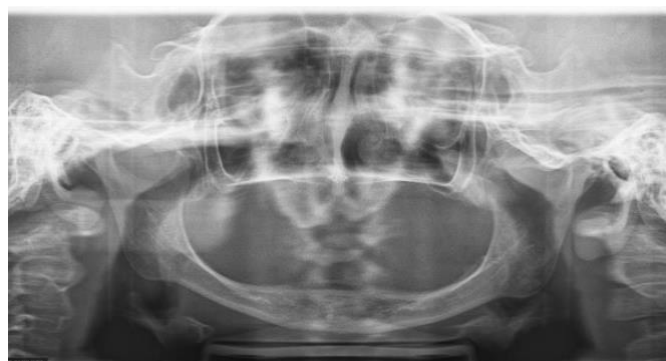

**Figure 7.** Appearance of scaling and spotting on the skin

An intraoral examination revealed anodontia; there were no teeth on the maxilla or the mandible, and there was no radiographically identified tooth germ. Furthermore, the patient suffered from dry mouth due to insufficient saliva production (Figs. 7, 8). The patient and his legal guardian were informed about the treatment options and their potential complications. Permission was received from the patient and his legal guardian for all procedures to be carried out, and they signed an informed consent document. Because the growth and development of the 5-year-old patient were ongoing, it was decided to apply a total prosthesis of the mandible and maxilla. Preliminary impressions were taken from the mandible and maxilla using irreversible hidrocolloid impression material (Kromopan; Lascod, Firenze, Italy) (Fig. 9).



**Figure 7.** Intraoral appearance of the patient

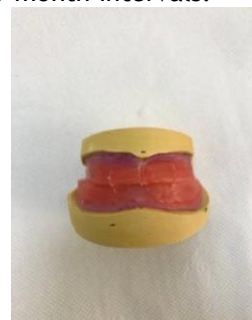

**Figure 8.** Panoramic radiograph of the patient

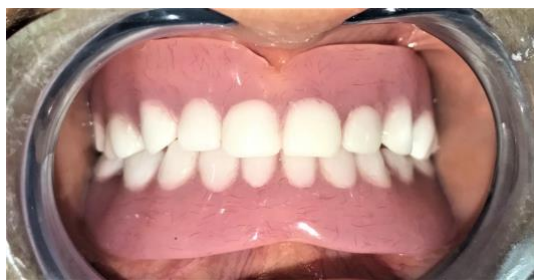

**Figure 9.** Preliminary impressions of the patient were taken with irreversible hidrocolloid

Plaster models were obtained from the impressions. Individual impression trays were prepared out of acrylic resin (PMMA) using the plaster models. By applying the impression compound (Kerr, USA) onto the prepared individual impression trays, sulcus shaping was performed. Then, using a specialized impression tray for border shaping, the second impressions of the mandible and maxilla of the patient were taken with zinc oxide material. By applying the boxing method to the measurements, a model was obtained by casting hard plaster. Acrylic bases were made for the models, and by using wax templates for the bases and using the Niswonger method, the vertical dimension of the patient was determined (Fig. 10). At the next stage, by placing acrylic artificial teeth suited to the morphology of primary teeth, the initial fitting of the patient was performed. The necessary modifications were made in the initial fitting process. To completely match the soft tissues of the patient, the next stage involved the wax model fitting process. After confirming the fit, the prosthesis manufacturing process started. The heat-polymerized acrylic material was applied according to the manufacturer's instructions, and the flasking process started. Care was taken while performing the polishing and finishing procedures. The prosthesis was given to the patient after confirming that the edges of the prosthesis were not sharp and the polishing work was excellent (Fig. 11). After handing over the prosthesis, periodic follow-ups were carried out on the 2nd day, in the 1st week, and in the 1st month, and modifications were made to areas where the prosthesis caused discomfort. Thereafter, the patient was followed up at 6-month intervals.



**Figure 10.** Plaster and wax models after taking vertical dimension measurements



**Figure 11.** Completed appearance of the total prosthesis of the patient

## Discussion

Hypohidrotic ectodermal dysplasia is a very rare clinical condition, with an average prevalence of 1/15,000. Its incidence in males is 1/50,000-100,000 (27). The autosomal recessive, autosomal dominant, and X-linked recessive forms of HED have been defined clinically. The most frequently observed form of HED is the X-linked recessive form, and it develops as a result of anomalies in the protein called ectodysplasin (EDA) caused by ED1 gene disorders found in the Xq12-q13 region. EDAR gene mutations found on the second chromosome and related EDAR protein anomalies cause hypohidrotic ectodermal dysplasia via both autosomal dominant and autosomal recessive inheritance (28). The department of genetics determined that our patient had hypohidrotic ectodermal dysplasia with autosomal recessive inheritance.

Şener (29) reported that the parents of 2 out of 3 cases they examined were first-degree relatives, but they did not show disease symptoms. The parents of our patient were non-consanguineous.

Dental symptoms in ED patients vary from hypodontia to anodontia (30, 31). Both primary and permanent teeth may be absent. However, the complete absence of both primary dentition and permanent dentition is rarely encountered (23, 32). Our patient displayed anodontia in both the primary and permanent teeth. A radiographical examination determined that he did not have any tooth germ.

In their study of 1,224 cases of patients aged 11-18 with ectodermal dysplasia, Nguyen-Nielsen et al. (33) reported dental anomalies in 79.4%, hypotrichosis (sparse hair on the body) in 11.4% and hypohydrosis (reduced sweating) in 5.9% of patients. In their study of 15 cases, Yavuz et al. (32) identified missing teeth in all cases, hypohydrosis in 13 cases, trichodysplasia in 13 cases, and abnormal fingers and nails in 12 cases. In our case, anodontia at both dentition stages, hypohydrosis (the patient's family reported that the patient was frequently hyperthermic), thin and sparse hair, and weak and brittle nail structure were present.

Early prosthetic rehabilitation is usually recommended starting at the age of 5. Nevertheless, based on the compliance of the child, prosthetics may be utilized at the ages of 3-4 (34). In such cases, it is important for the child to be psychologically and mentally mature enough to accept treatment (30, 32,

35). In our case, the treatment started at the age of 5, and the patient was followed-up periodically at 6-month intervals so that the prosthetics could be adjusted according to his growth and development.

In the growth and development process, prosthetic rehabilitation of HED cases is recommended to repair the vertical and sagittal skeletal relationships, for aesthetic rehabilitation, and for modification of chewing and speaking activity (34). In ED patients, the main objective is to improve chewing function and aesthetics. The appropriate treatment is multi-stage, and various fields of expertise are needed to identify and administer an optimum treatment. The required type of treatment is decided based on the state of malocclusion, which depends on the severity of the functional and aesthetic problems caused by the lack of teeth (30, 34, 36-38).

In most previous studies, removable partial or total prosthetics have been preferred to compensate for missing teeth (15, 22). The prosthetics that are used should be modified in the presence of newly erupting teeth to ensure compatibility with the development of alveolar tissues and jaws (39). In our case, a total prosthesis was preferred due to anodontia.

In cases of missing teeth in ED patients whose growth and development are ongoing, to resolve psychological, aesthetic, and functional problems, even before puberty, implant treatments are among the alternative treatment options (36).

In a patient with anhidrotic type ectodermal dysplasia, Alcan et al. (40) placed 4 implants between the mental foramina despite the presence of crest deficiency in the buccolingual direction for the purpose of achieving prosthetic stabilization. They followed bone resorptions and appositions in the symphysis region for 6 years. It was determined that, throughout growth and development, the change in the symphysis region was limited to 1-2 mm of bone resorption or apposition, a situation that does not disturb implant stabilization.

Smith et al. (41) applied 1 implant to a 5-year-old patient with hypohidrotic ectodermal dysplasia, and they reported that the osteointegration of this implant was not completed, whereas resorption increased.

Based on the published literature, in general, removable prosthetics during the growth period of children and implant-supported prosthetics after the completion of the growth period are recommended (30, 34, 36-38, 42).

## Conclusions

Missing teeth are frequently found in patients with hypohidrotic ectodermal dysplasia. However, anodontia is rarely encountered. Due to lack of teeth (oligodontia, anodontia), malnutrition, aesthetic problems, deficient chewing function, phonation problems, psychological problems, and malnutrition-related delays in physical development, retardation may be observed in these patients. To prevent these problems, early prosthetic intervention has gained importance. Especially in pediatric patients, the

patient should be prepared for treatment outcomes and supported psychologically. In this case report, in the presence of anodontia, a removable total prosthesis (a non-invasive treatment option) was applied. Production of endosseous implants was postponed for a later time following further growth and development of the patient.

**Acknowledgments:** This study was presented as a full-text oral presentation at the 1<sup>st</sup> International Dental Research and Health Sciences Congress held between 20-22 May 2021.

**Patient Consent for Publication:** Written informed consent was obtained from the patient.

**Peer-review:** Externally peer-reviewed.

**Author Contributions:** Conception - D.G.; Design -E.A.; Supervision - Z.S.P.; Materials - D.G.; Data Collection and/or Processing - E.A.; Analysis and/or Interpretation - Z.S.P.; Literature Review - D.G.; Writer - Z.S.P.; Critical Review - D.G.

**Conflict of Interest:** No conflict of interest was declared by the authors.

**Financial Disclosure:** The authors declared that this study has received no financial support.

## References

- Hickey AJ, Salter M. Prosthodontic and psychological factors in treating patients with congenital and craniofacial defects. *J Prosthet Dent*. 2006; May 95(5): 392-6. (Crossref)
- Itin PH, Fistarol SK. Ectodermal dysplasias. *Am J Med Genet C Semin Med Genet* 2004; 131: 45-51. (Crossref)
- Suri S, Carmichael RP, Tompson BD. Simultaneous functional and fixed appliance therapy for growth modification and dental alignment prior to prosthetic habilitation in hypohidrotic ectodermal dysplasia: A clinical report. *J Prosthet Dent*. 2004; 92(5): 428-33. (Crossref)
- Duijff P, Bokhoven H. Ectodermal dysplasia: Skinny models on the catwalk. *Drug Discovery Today: Disease Models* 2005; 2(2): 111-118. (Crossref)
- Vieira KA, Teixeira MS, Guirado CG, Gaviao MB. Prosthodontic treatment of hypohidrotic ectodermal dysplasia with complete anodontia: case report. *Quintessence Int* 2007;38:75-80.
- Pigno MA, Blackman RB, Cronin RJ, Cavazos E. Prosthodontic management of ectodermal dysplasia: A review of the literature. *J Prosthet Dent*. 1996; 76(5): 541-5. (Crossref)
- NaBadalung DP. Prosthodontic rehabilitation of an anhidrotic ectodermal dysplasia patient: A clinical report. *J Prosthet Dent*. 1999; 81(5): 499-502. (Crossref)
- Vergo TJ. Prosthodontics for pediatric patients with congenital/developmental orofacial anomalies: A long-term follow-up. *J Prosthet Dent*. 2001; 86(4): 342-7. (Crossref)
- Imirzalioglu P, Uckan S, Haydar SG. Surgical and prosthodontic treatment alternatives for children and adolescents with ectodermal dysplasia: A clinical report. *J Prosthet Dent*. 2002; 88(5): 569- 72. (Crossref)
- Argenziano G, Monurro MR, Pazienza R, Delfino M. A case of probable autosomal recessive ectodermal dysplasia with corkscrew hairs and mental retardation in a family with tuberous sclerosis. *J Am Acad Dermatol* 1997; 38(2): 344-348. (Crossref)
- Priolo M. Ectodermal dysplasias: an overview and update of clinical and molecular-functional mechanisms. *Am J Med Genet A* 2009; 149: 2003-13. (Crossref)
- Fete M, Hermann J, Behrens J, Huttner KM. X-linked hypohidrotic ectodermal dysplasia (XLHED): Clinical and diagnostic insights from an international patient registry. *Am J Med Genet A* 2014; 164: 2437-42. (Crossref)
- Yavuz I, S. Kiralp, Z. Baskan, "Hypohidrotic ectodermal dysplasia: A case report" *Quintessence International* 2008; 39(1): 81-6
- Dai YS, Liang MG, Gellis SE, Bonilla FA, Schneider LC, Geha RS, Orange JS. Characteristics of mycobacterial infection in patients with immunodeficiency and nuclear factor-kB essential modular mutation, with or without ectodermal dysplasia. *J Am Acad Dermatol* 2004; 51(5): 718- 22. (Crossref)
- Altun C. 7 yaşındaki bir hidrotik ektodermal displazi hastasında protetik tedavi yaklaşımı (olgu raporu). *Dicle Dışhekimliği Dergisi*. 2009;10(2): 25-8.
- Johnson EL, Roberts MW, Guckes, AD, Bailey LJ, Phillips CL, Wrig JT. Analysis of craniofacial development in children with hypohidrotic ectodermal dysplasia. *American Journal of Medical Genetics*. 2002;112:327-34. (Crossref)
- Itthagarun A, King NM. Ectodermal dysplasia: A review and case report. *Quintessence Int*. 1997;28(9):595- 602.
- Sweeney IP, Ferguson JW, Heggie AA, Lucas JO. Treatment outcomes for adolescent ectodermal dysplasia patients treated with dental implants. *Int J Paediatr Dent*. 2005;15(4):241-8. (Crossref)
- Levin LS. Dental and oral abnormalities in selected ectodermal dysplasia syndromes. *Birth Defects*. 1988;24:205-27.
- Güler N, Cildir S, Iseri U, Sandalli N, Dilek O. Hypohidrotic ectodermal dysplasia with bilateral impacted teeth at the coronoid process: a case rehabilitated with mini dental implants. *Oral Surg Oral Med Oral Pathol Oral Radiol Endod*. 2005;99(5):34-8. (Crossref)
- Tsai PF, Chiou HR, Tseng CC. Oligodontia--a case report. *Quintessence Int*. 1998;29(3):191-3.
- Över H, Akşit KS, Ektodermal displazi hastalarında protetik rehabilitasyon: olgu sunumu, Atatürk Üniv. Dış Hek. Fak. Derg. *J Dent Fac Atatürk Üni* 2012;22 (2): 180-184.
- Baygın Ö, Ülker E, Tulunoğlu Ö. Ektodermal displazi: 4 olgu bildirimi. *GÜ Dış Hek Fak Derg* 2009;26(1): 59-65.
- Başkan Ülkü Z., Yavuz İ. Ektodermal Displazili Hastalarda Protetik Yaklaşımlar. *Atatürk Üniv Dış Hek Fak Derg* 2011;21: 57-61.
- Turfaner M, Akşit KS. Tutuculuğu Moloplast-B ile sağlanmış müteharrik dişüstü protezlerin çiğneme performansı üzerine etkileri: 2 yıllık gözlemler. *İ.Ü Dışhekimliği Fakültesi Dergisi* 1990;24(4):186-190.
- Akşit KS, Göksoy V, Turfaner M. Parsiyel anadonti (hipodonti) vakalarında uygulanan tutuculuğu Moloplast-B ile sağlanmış müteharrik dişüstü protezlerde periodontolojik araştırmalar: 2 yıllık gözlemler. *İÜ Dışhekimliği Fakültesi Dergisi* 1996; 24(3): 128-133.
- Schneider H. Hypohidrotic ectodermal dysplasia. <http://www.orpha.net> 18.06.2014.
- Esen İ, Özcanlı Ö, Hipohidrotik Ektodermal Displazi: Olgu Sunumu, *Firat Tıp Derg/Firat Med J* 2015; 20(2): 116-118.
- Sener S. Üç Kız Çocukta Hipohidrotik Ektodermal Displazi. *Düzce Univ. Tıp Derg*. 2007;3:38-40.
- Tarjan I, Gabris K, Rozsa N. Early prosthetic treatment of patients with ectodermal dysplasia: A clinical report. *J Prosthet Dent* 2005;93(5):419- 424. (Crossref)
- Hobkirk JA, Nohl F, Bergendal B, Storhaug K, Richter MK. The management of ectodermal dysplasia and severe hypodontia. *International Conference Statements. J Oral Rehabil* 2006;33(9): 634-637. (Crossref)

32. Yavuz I, Baskan Z, Ulku R. Ectodermal dysplasia: Retrospective study of fifteen cases. *Arch Med Res* 2006;37(3):403-409. ([Crossref](#))
33. M. Nguyen-Nielsen et al. The prevalence of Xlinked hypohidrotic ectodermal dysplasia (XLHED) in Denmark, 1995-2010. *European Journal of Medical Genetics* 2013;56: 236-42. ([Crossref](#))
34. Ramos V, Giebink DL, Fisher JG, Christensen LC. Complete dentures for a child with hypohidrotic ectodermal dysplasia: a clinical report. *J Prosthet Dent* 1995;74:329-31. ([Crossref](#))
35. Hickey AJ, Vergo TJ, Jr. Prosthetic treatments for patients with ectodermal dysplasia. *J Prosthet Dent* 2001;86:364-8. ([Crossref](#))
36. Balshi TJ, Wolfinger GJ. Treatment of congenital ectodermal dysplasia with zygomatic implants: a case report. *Int J Oral Maxillofac Implants* 17: 277-281, 2002.
37. Becktor KB, Becktor JP, Keller EE. Growth analysis of a patient with ectodermal dysplasia treated with endosseous implants: a case report. *Int J Oral Maxillofac Implants* 16: 864-874, 2001.
38. Bonilla ED, Guerra L, Luna O. Overdenture prosthesis for oral rehabilitation of hypohidrotic ectodermal dysplasia: a case report. *Quintessence Int* 28: 657-665, 1997.
39. Murdock S, Lee JY, Guckes A, Wright JT. A costs analysis of dental treatment for ectodermal dysplasia. *J Am Dent Assoc* 2005; 136: 1273-6. ([Crossref](#))
40. Alcan T, Basa S, Kargul B. Growth analysis of a patient with ectodermal dysplasia treated with endosseous implants: 6- year followup. *J Oral Rehabil* 33: 175-182, 2006. ([Crossref](#))
41. Smith RA, Vargervik K, Kearns G, Bosch C, Koumjian J. Placement of an endosseous implant in a growing child with ectodermal dysplasia. *Oral Surg Oral Med Oral Pathol*.75: 669-673, 1993. ([Crossref](#))
42. Ayna E, Meşe A, Ayna B, Çelenk S, Bolgöl B. Complete and Removable Partial Dentures for Patients with Ectodermal Dysplasia: 2 Case Reports. *Balk J Stom*, 2007; 11:141-144